

Skin Necrosis following Rhinoplasty

Mohamed A. Mrad, MD, FRCSC,
MBA, FACS
Mohammed A. Almarghoub,
MBBS

Summary: Rhinoplasty is one of the most common cosmetic procedures performed by plastic surgeons worldwide. It is among the top 5 common aesthetic procedures in the United States. The complications rate in rhinoplasty is 8–15%, and a majority of these complications are not life-threatening. One of the rare complications reported is skin necrosis. In our article, we report 2 cases that developed skin necrosis on the nasal dorsum following rhinoplasty. (*Plast Reconstr Surg Glob Open* 2019;7:e2077; doi: 10.1097/GOX.0000000000002077; Published online 8 February 2019.)

INTRODUCTION

Rhinoplasty is one of the most common cosmetic procedures performed by plastic surgeons worldwide.¹ The healing process involves different types of tissues; therefore, rhinoplasty is considered a challenging procedure for achieving good results. As in any surgical operation, complications can occur. The complications rate in rhinoplasty is found to be 8–15%.² Complications can be classified as early and late. Early complications are mostly related to intraoperative sterility and surgical techniques, while late complications are related to the resorption of cartilage.³ The majority of these complications, such as acne exacerbation, nasal tip paresthesia, and periorbital hyperpigmentation are not life-threatening, whereas life-threatening conditions, such as pneumothorax, and subarachnoid hemorrhage, are rarely encountered.^{4,5} One of the rare complications is skin necrosis.¹ In our article, we report 2 cases that developed skin necrosis on the nasal dorsum following rhinoplasty. Interestingly, nasal dorsum is not the usual place for such a complication. Here, we discuss ways to treat it and also delineate the steps to decrease the chances of such an event.

CASE 1

A 34-year-old female patient had a complaint of nasal deformity. She underwent secondary rhinoplasty where the deviated cartilaginous septum was corrected by submucosal resection, forming an L-shape. The deviated bony septum was corrected by lateral low-to-high osteotomies. A part of the harvested cartilage was used as columellar

strut graft; the rest was diced and wrapped in one layer of Surgicel, which was then used as an on-lay graft to augment the nasal dorsum as in the Turkish delight technique.⁶ Defatting was done for the bulbous tip, which was also refined by transdomal sutures. After skin closure, a metal splint was applied in the usual manner. On follow-up, removal of the splint revealed a 0.7 × 0.4 cm skin necrosis on the nasal dorsum. Local wound dressing was done, and the patient was prescribed Contractubex. After 6 months, the skin defect had healed, but a noticeable scar remained. Autogenous fat graft mixed with purified platelet-rich plasma (PRP) was injected into the scarred area. Eventually, the patient developed an acceptable scar (Fig. 1).

CASE 2

An open rhinoplasty was planned for a 26-year-old man with nasal deformity who was addicted to smoking. Tip work and osteotomies were performed as in the first case; however, no tip defatting was done. After skin closure, a metal splint was applied, as in the first case. On follow up, a 0.1 × 0.2 cm skin necrosis was found just above the supratip area, which healed spontaneously. After 1 month, the scarred area was excised under local anesthesia, followed by primary closure. The patient developed an acceptable scar (Fig. 2).

DISCUSSION

Cutaneous complications, following rhinoplasty is usually minor and transit.⁷ Skin necrosis is one of these rare and serious complications that have worried both patients and doctors. Smoking has a deleterious effect on skin surgeries.⁸ One of our patients was a smoker that might have contributed to the skin necrosis. In our cases, the Turkish delight technique was used to augment the nasal dorsum; a metal external nasal splint was applied postoperatively. The same technique, with external nasal splint, was also used in the previously reported cases. In this technique, the cartilage autografts are used cover the nasal dorsum to achieve a

From the Plastic and Reconstructive Surgery Section, Department of Surgery, King Faisal Specialist Hospital & Research Centre, Riyadh, Saudi Arabia.

Received for publication September 24, 2018; accepted October 22, 2018.

Copyright © 2019 The Authors. Published by Wolters Kluwer Health, Inc. on behalf of The American Society of Plastic Surgeons. This is an open-access article distributed under the terms of the Creative Commons Attribution-Non Commercial-No Derivatives License 4.0 (CCBY-NC-ND), where it is permissible to download and share the work provided it is properly cited. The work cannot be changed in any way or used commercially without permission from the journal.

DOI: 10.1097/GOX.0000000000002077

Disclosure: The authors have no financial interest to declare in relation to the content of this article. The Article Processing Charge was paid by the authors.

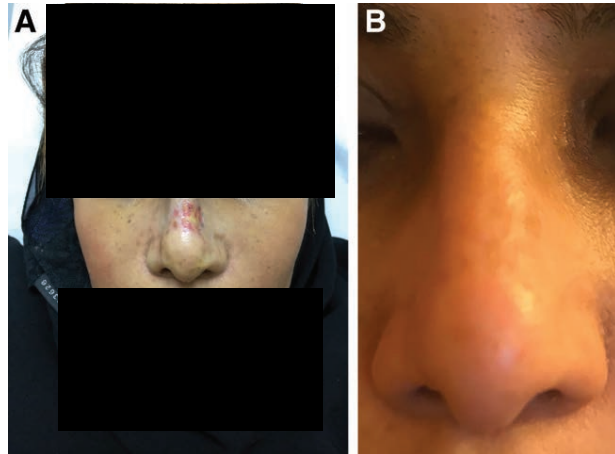


Fig. 1. A, Appearance of skin necrosis in one-week postrhinoplasty. B, Appearance of skin in the first postoperative year.

smooth straight contour of the nasal dorsum. We think that overcorrection by the graft placed in the nasal dorsum with tight metal splint might affect the blood supply. In addition, postoperative edema may further affect skin survival.

Conservative management and revision surgeries after scar maturation were done to manage skin necrosis. Furthermore, a combination of PRP and fat graft can enhance wound healing.^{9,10} However, more studies are needed to understand the true impact of PRP-fat graft combination on skin necrosis.

In the first case, we managed conservatively for 6 months. Then a combination of fat graft and PRP was used to manage the resultant scar. However, in the second case, the defect healed spontaneously. In a previous report, such scars were managed immediately by debridement, and closure either with primary sutures or by a local rotation flap.¹

We think that multiple factors contribute to local skin necrosis postrhinoplasty. We recommend that the patients should quit smoking before the operation and the surgeons should avoid the application of tight metal external splints on large dorsal nasal grafts. To avoid complications, we shifted from metal splints to thermoplastic splints (Fig. 3). Being softer and more malleable, thermoplastic splints can accommodate the postoperative edema better; the multiple pores also cause less pressure on the nasal dorsum.

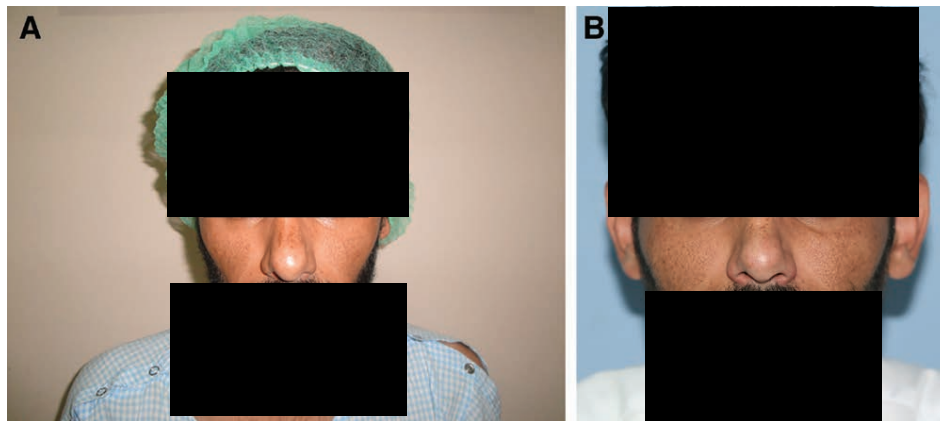


Fig. 2. A, Appearance of skin necrosis in one-week postrhinoplasty. B, Appearance of skin in the first postoperative year.

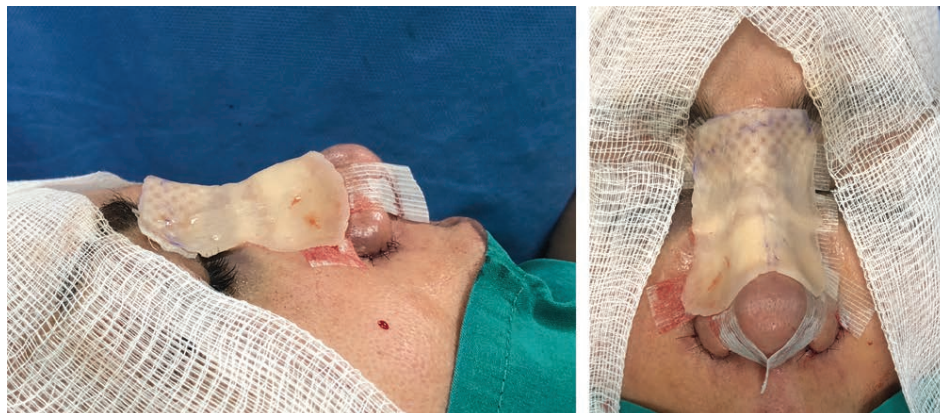

Fig. 3. Thermoplastic splint is applied for a patient.

SUMMARY

Skin necrosis following rhinoplasty is a rare complication. Smoking and pressure applied by the nasal splint could contribute to this deleterious complication. Smoking cessation and decreased pressure on the nasal dorsum are suggested to avoid this complication.

Mohammed A. Almarghoub, MBBS

Plastic and Reconstructive Surgery Section
Department of Surgery
King Faisal Specialist Hospital & Research Centre
P.O. Box 3354, Riyadh 11211, Saudi Arabia
E-mail- Almarghoubm@gmail.com

REFERENCES

1. Eskitascioglu T, Kemaloglu A. Skin necrosis in nasal dorsum following rhinoplasty. *Eur J Plast Surg*. 2010;33:49–51.
2. Becker D. *Complication in Rhinoplasty*. 2nd ed. Papel I, Frodel J, Holt G, eds. 2002.
3. Rettinger G. Risks and complications in rhinoplasty. *GMS Curr Top Otorhinolaryngol Head Neck Surg*. 2007;6:Doc08.
4. Koçak A, Gürlek A, Kutlu R, et al. An unusual complication of septorhinoplasty: massive subarachnoid hemorrhage. *Ann Plast Surg*. 2004;53:492–495.
5. Eroglu L, Akbas H, Guneren E, et al. An unexpected complication after rhinoplasty: pneumothorax. *Plast Reconstr Surg*. 2002;110:992–993.
6. Erol ÖO. The Turkish delight: a pliable graft for rhinoplasty. *Plast Reconstr Surg*. 2000;105:2229–2241.
7. Nemati S, Golchay J, Alizadeh A. Frequency of minor skin and soft tissue complications in facial and periorbital area after septorhinoplasty. *Iran J Otorhinolaryngol*. 2012;24:119–124.
8. Silverstein P. Smoking and wound healing. *Am J Med*. 1992;93:22S–24S.
9. Cervelli V, Gentile P, De Angelis B, et al. Application of enhanced stromal vascular fraction and fat grafting mixed with PRP in post-traumatic lower extremity ulcers. *Stem Cell Res*. 2011;6:103–111.
10. Cervelli V, Gentile P, Scioli MG, et al. Application of platelet-rich plasma in plastic surgery: clinical and *in vitro* evaluation. *Tissue Eng Part C Methods*. 2009;15:625–634.